

# Macular Buckle for Retinal Detachment Related to Macular Hole in Highly Myopic Eyes

Old idea, new interest?

**BY CARLOS MATEO, MD**

*In this issue of Retina Today, Carlos Mateo, MD, details his surgical technique for macular buckling in highly myopic patients with retinal detachment due to macular hole.*

*We extend an invitation to readers to submit pearls for publication in Retina Today. Please send submissions for consideration to Dean Elliott, MD ([dean\\_elliott@meei.harvard.edu](mailto:dean_elliott@meei.harvard.edu)); or Ingrid U. Scott, MD, MPH ([iscott@hmc.psu.edu](mailto:iscott@hmc.psu.edu)). We look forward to hearing from you.*



— Dean Elliott, MD; and Ingrid U. Scott, MD, MPH

**H**igh myopia is generally defined as an ocular axial length of at least 26 mm or a refractive error greater than -6.00 D. It has been shown that, in some highly myopic eyes, the centrifugal action of staphyloma formation is counteracted by the action of 3 main forces: (1) posterior vitreous traction, (2) internal limiting membrane (ILM), and (3) stretched retinal arteries.

Retinal detachment (RD) secondary to macular hole is more frequent in myopic eyes and is more likely to develop in Asian patients. Several surgical techniques have been described for the treatment of these patients, including pars plana vitrectomy (PPV) with posterior hyaloid removal, ILM peeling, and macular buckling.

Macular buckling is an old surgical technique, the goal of which is to counteract the pulling effect of the staphyloma.<sup>1-3</sup> Since 1982, PPV (with various additional procedures) has generally been considered the preferred surgical approach for the treatment of RD due to macular hole in highly myopic eyes.<sup>4</sup> Although some surgeons continued performing and developing macular buckling

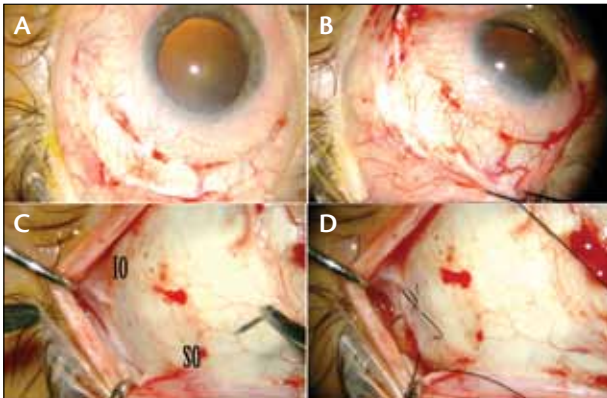
surgery, it was commonly considered technically challenging probably because of the difficulties in achieving the correct placement of the macular buckle.<sup>5</sup> However, in recent years there has been renewed interest in macular buckling surgery, and in the past 2 years several techniques have been described.<sup>6-11</sup>

## **BASIC TECHNIQUE**

### **Exposure of the Superotemporal Scleral Quadrant**

A 140° superotemporal conjunctival peritomy is performed with separation of Tenon capsule (Figure 1A). The superotemporal quadrant is selected with the aim of avoiding the inferior oblique muscle, which runs posteriorly and laterally along the entire inferotemporal quadrant. The superior and temporal rectus tendon muscles are hooked with a 3-0 silk suture to help with the exposure of the superotemporal scleral quadrant (Figure 1B). After this step, we localize the insertion of the 2 oblique muscles, and between them a 5-0





**Figure 1.** Initial steps of macular buckling surgery. Superotemporal incision of the conjunctiva, 2.5 mm from the limbus (A). Pulling the superior and temporal hooked muscles to expose the superotemporal quadrant (B). The insertion of the tendons of the inferior and superior oblique muscles (C). At 20 mm from the limbus, a mattress suture pointing to the macula is placed (D).

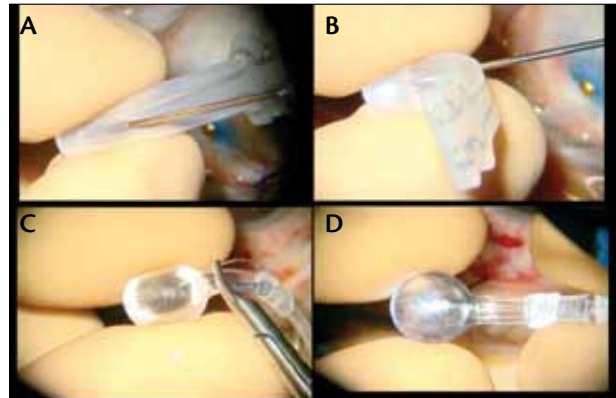
nylon suture pointing toward the macular area is placed (Figures 1C and 1D). Although this suture can be positioned after vitrectomy, we prefer to do it before the eye has been opened. At this point, extra care must be taken to avoid the vortex veins near the tendon of the superior oblique muscle.

### Pars Plana Vitrectomy

Although PPV is not absolutely necessary, we prefer to perform it to release the traction from the posterior hyaloid and the ILM. Any instrument diameter (20 gauge, 23 gauge, 25 gauge, or 27 gauge) can be used, but the instrument must have the necessary length to be able to reach the posterior pole of the eye. The posterior hyaloid can be removed with the assistance of triamcinolone. Due to the consistency of the posterior hyaloid in some cases, some surgeons prefer to use a Tano diamond-dusted scraper to peel away the posterior hyaloid that remains adherent to the inner surface of the retina.

### Dyes

Brilliant blue is a vital dye employed to stain the ILM. It is often used in Europe, but it is not available in the United States, where indocyanine green (ICG) at a low concentration is used instead. To prevent the dye from spilling into the subretinal space, there are 2 techniques that can be used: (1) injecting a small bubble of perfluorocarbon liquid to tamponade the macular hole or (2) mixing the dye with viscoelastic so that the viscosity will prevent the dye from passing into the subretinal space.<sup>12</sup>



**Figure 2.** Macular buckles. Ando Plombe (A). Ando Plombe with an optical fiber in the center of the indenting platform (B). AJL macular buckle (C). AJL macular buckle with the optical fiber inside the groove (D).

---

Macular buckling is a reversible surgical technique that can improve the anatomic and functional outcomes of highly myopic patients with retinal detachment due to macular hole by counteracting the staphyloma action.

---

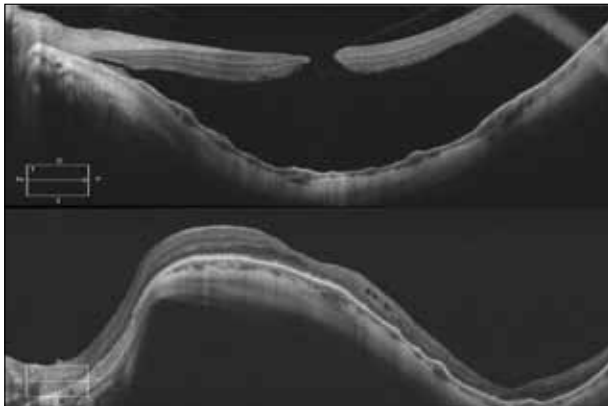
### ILM Peeling

The injection of perfluorocarbon liquid into the vitreous cavity over the macula stabilizes the retina when it is detached, providing counteraction when ILM removal is performed.<sup>13</sup> It also displaces subretinal fluid to the periphery. In the case of a superior quadrant retinal detachment, a small peripheral retinotomy can be performed to remove the subretinal fluid. This maneuver eliminates the need to drain the fluid through the macular hole, which can lead to macular hole enlargement due to the high viscosity of the fluid and trauma to the borders of the hole.

### Placement of the Macular Buckle

Different types of macular buckle have been described in the literature. Figure 2 shows the Ando Plombe (Ondeko Corporation Japan) and the AJL macular buckle (AJL Ophthalmic Spain).

The Ando Plombe explant is a silicone rod with metallic wires inside that allow it to be bent to obtain the desired buckling effect of the macular area. To help with its placement, we insert an optical fiber in the center of the platform (Figures 2A and 2B). The light can be switched on



**Figure 3.** Spectral-domain OCT showing preoperative high density scan in a patient with RD and macular hole in the center of a staphyloma (A). After macular buckling, the retina remains attached and the macular hole is closed (B).

and off, allowing the correct placement of the platform via transillumination. The AJL macular buckle is made of silicone-coated PMMA, which makes it rigid and does not allow bending. It has a groove in the indenting platform to insert an optical fiber (Figures 2C and 2D).

The explant is inserted in the superotemporal quadrant, across the previously placed 5-0 nylon scleral suture. When inserting the plombe, special care must be taken to avoid damaging the vascular structures or the optic nerve. The indenting head of the plombe is adjusted and positioned underneath the macula. The explant can be mobilized carefully until the indenting platform is seen under the macular area by lighting through the optical fiber. The scleral suture placed at the beginning of the procedure is the axis, and a second suture must be placed in the anterior part of the buckle shaft to help guide the platform to the center of the macula. When the macular indentation is in the correct place, the optical fiber is removed. Additional sutures can be placed to secure the buckle shaft.

### Completion of the Procedure

The peripheral retina must be examined for any holes or breaks that may require laser treatment. A perfluorocarbon liquid-air exchange is then performed. Finally, nonexpansible concentration of gas or silicone oil can be used as a temporary tamponade. The patient is instructed to position face-down for 5 days in the postoperative period (Figure 3).

### SUMMARY

Macular buckling is a reversible surgical technique that can improve the anatomic and functional outcomes of highly myopic patients with retinal detachment due to macular hole by counteracting the staphyloma action.

**Weigh in on this topic now!**



Direct link: <https://www.research.net/s/RT16>

**1. Do you perform macular buckling in patients with retinal detachment secondary to macular hole in myopic eyes?**

- Yes  
 No

Further comparative studies of different techniques may help to improve this surgical approach that has recently gained renewed interest among vitreoretinal surgeons. ■

*Carlos Mateo, MD, is a vitreoretinal surgeon at Instituto de Microcirugia Ocular and an Associate Professor of Ophthalmology at the Autonoma University of Barcelona. Dr. Mateo states that he has no financial interest in the products or companies mentioned. He may be reached at email: [carlosmateo@me.com](mailto:carlosmateo@me.com).*

*Dean Elliott, MD, is Associate Director of the Retina Service, Massachusetts Eye and Ear Infirmary, Harvard Medical School, and is a Retina Today Editorial Board member. He may be reached by phone: +1 617 573-3736; fax: +1 617 573 3698; or via email at [dean\\_elliott@meei.harvard.edu](mailto:dean_elliott@meei.harvard.edu).*

*Ingrid U. Scott, MD, MPH, is a Professor of Ophthalmology and Public Health Sciences, Penn State College of Medicine, Department of Ophthalmology, and is a Retina Today Editorial Board member. She may be reached by phone: +1 717 531 8783; fax: +1 717 531 5475; or via email at [iscott@hmc.psu.edu](mailto:iscott@hmc.psu.edu).*

- Rosengren B. The silver plomb method in macular holes. *Trans Ophthalmol Soc U.K.* 1966;86:49-53.
- Klötli R. Silver clip for central retinal detachments with macular hole. *Mod Probl Ophthalmol.* 1974;12(0):330-336.
- Feman SS, Hepler RS, Straatsma BR. Rhegmatogenous retinal detachment due to macular hole. Management with cryotherapy and a Y-shaped sling. *Arch Ophthalmol.* 1974;91(5):371-372.
- Gonvers M, Machermer R. A new approach to treating retinal detachment with macular hole. *Am J Ophthalmol.* 1982;94(4):468-472.
- Theodosiadis GP, Theodosiadis PG. The macular buckling procedure in the treatment of retinal detachment in highly myopic eyes with macular hole and posterior staphyloma: mean follow-up of 15 years. *Retina.* 2005;25(3):285-289.
- Tanaka T, Ando F, Usui M. Episcleral macular buckling by semirigid shaped-rod explant for recurrent retinal detachment with macular hole in highly myopic eyes. *Retina.* 2005;25(2):147-151.
- Devin F, Tsui I, Morin B, Duprat JP, Hubschman JP. T-shaped scleral buckle for macular detachments in high myopes. *Retina.* 2011;31(1):177-180.
- Siam AL, El Maamoun TA, Ali MH. Macular buckling for myopic macular hole retinal detachment: a new approach. *Retina.* 2012;32(4):748-753.
- Stirpe M, Ripandelli G, Rossi T, Cacciamani A, Orciuolo M. A new adjustable macular buckle designed for highly myopic eyes. *Retina.* 2012;32(7):1424-1427.
- El Rayes EN. Suprachoroidal buckling in managing myopic vitreoretinal interface disorders: 1-year data [published online ahead of print April 23, 2013]. *Retina.*
- Parolini B, Frisina R, Pinackatt S, Mete M. A new L-shaped design of macular buckle to support a posterior staphyloma in high myopia. *Retina.* 2013;33(7):1466-1470.
- Facino M, Mochi B, Lai S, Terrile R. A simple way to prevent indocyanine green from entering the subretinal space during vitrectomy for retinal detachment due to myopic macular hole. *Eur J Ophthalmol.* 2004;14(3):269-271.
- Brazitikos PD, Androudi S, Dimitrakos SA, Stangos NT. Removal of the internal limiting membrane under perfluorocarbon liquid to treat macular-hole-associated retinal detachment. *Am J Ophthalmol.* 2003;135(6):894-896.