

Clinical and Molecular Outcomes After Combined Intense Pulsed Light Therapy With Low-Level Light Therapy in Recalcitrant Evaporative Dry Eye Disease With Meibomian Gland Dysfunction

Sharon D'Souza, MS, FCE,* Archana Padmanabhan Nair, Msc,† Gowtham Iyappan, PhD,‡ Mor M. Dickman, MD, PhD,‡ Prashansa Thakur, MS,* Ritika Mullick, MS,* Gairik Kundu, MS, FCE,* Swaminathan Sethu, PhD,† Arkasubhra Ghosh, PhD,† and Rohit Shetty, FRCS, PhD*

Purpose: Dry eye disease (DED) is a leading cause of ocular morbidity worldwide. This study evaluates the effects of combined light therapy [intense pulsed light (IPL) and low-level light therapy (LLLT)] on clinical and molecular outcomes in evaporative DED with meibomian gland dysfunction (MGD).

Methods: This prospective study evaluated 94 eyes (47 subjects) with chronic MGD treated with combined light therapy. Patients underwent a detailed evaluation of MGD and DED using the Ocular Surface Disease Index, dry eye tests—tear breakup time and Schirmer test, ocular surface staining, meibomian gland expressibility scoring, and meibography. Patients underwent a single session of combined light therapy (IPL + LLLT treatment) using the Eye-light device. All these tests were repeated at 3 and 6 months after treatment. Tear fluid and ocular surface wash samples were collected from a subset of patients before and after treatment for cellular and secreted immune factor profiling by flow cytometry.

Results: Combined light therapy (IPL + LLLT) demonstrated a marked improvement in the clinical metrics studied. Three months after treatment, Ocular Surface Disease Index showed a significant reduction in 95.6% ($P < 0.0001$), tear breakup time increased in 72.3% ($P < 0.0001$), and meibomian gland expressibility scoring increased in 80.8% ($P < 0.0001$) of the eyes. These effects were observed to be sustained during the 6-month follow-up visit.

Significant ($P < 0.05$) reduction in tear fluid levels of interleukin-1 β , interleukin-17F, and MMP9; MMP9/TIMP1 ratio; and ocular surface B-cell proportions was observed.

Conclusions: Combined light therapy shows promising results in patients with chronic MGD and DED, even in recalcitrant cases. Clinical and molecular factor alterations support the improved symptomatology and reduced inflammation.

Key Words: meibomian gland dysfunction, intense pulsed light, low-level light therapy, molecular factors, immune cells

(*Cornea* 2021;00:1–8)

Meibomian gland dysfunction (MGD) is a leading cause of evaporative dry eye disease (DED).^{1,2} It is characterized by a reduction in the quantity or quality of meibum secretion from meibomian glands and/or meibomian gland obstruction.³ This can result in changes in the tear film, especially the lipid component, ocular surface inflammation, and evaporative DED.⁴ MGD is associated with specific clinical signs such as altered meibomian gland secretion, meibomian gland atrophy, and changes in lid morphology based on which the disease is graded.³ Severe chronic MGD can also result in keratoconjunctivitis with conjunctival congestion, inflammatory infiltration of the cornea, and neovascularization.^{5,6} Adequate and long-term treatment of MGD is essential to reduce the associated ocular surface inflammation.⁷ The DED associated with chronic severe MGD can also significantly affect the patient's quality of life, certain activities of daily living and economic productivity.⁸

The treatment of this condition aims to improve the quality and quantity of meibum secretions, thereby improving the stability of the tear film and reducing the associated inflammation and ocular surface discomfort. The conventional treatment of MGD includes warm compress on the eyelids,⁹ topical antibiotic ointment application on lid margins, lid hygiene, topical anti-inflammatory and steroids, artificial tear supplementation, and even oral antibiotics in severe cases.^{10,11} However, there is a subset of patients in whom medical treatment does not give adequate relief

Received for publication April 30, 2021; revision received October 23, 2021; accepted October 25, 2021.

From the *Department of Cornea and Refractive Surgery, Narayana Nethralaya Eye Hospital, Bangalore, India; †GROW Research Laboratory, Narayana Nethralaya Foundation, Bangalore, India; and ‡University Eye Clinic, Maastricht University Medical Centre + MERLN Institute for Technology-Inspired Regenerative Medicine, Maastricht, the Netherlands.

Supported by the Narayana Nethralaya Foundation, Bangalore, India. The funders had no role in study design, data collection, and analysis.

The authors have no conflicts of interest to disclose.

Supplemental digital content is available for this article. Direct URL citations appear in the printed text and are provided in the HTML and PDF versions of this article on the journal's Web site (www.corneajrnl.com).

The manuscript has been read and approved by all the authors.

Correspondence: Sharon D'Souza, MS, FCE, Department of Cornea and Refractive Surgery, Narayana Nethralaya Eye Hospital, Narayana Nethralaya, 121/C Chord Rd, Rajajinagar, Bangalore 560010, India Email (e-mail: drsharondsouza@gmail.com).

Copyright © 2021 Wolters Kluwer Health, Inc. All rights reserved.

necessitating alternate treatment methods. Procedural therapies, such as intraductal probing,¹² automated thermal pulsation therapy,^{13,14} and intense pulsed light (IPL) therapy, have shown promising results in certain cases.^{15,16}

IPL therapy is a relatively new procedural therapy which is widely used in dermatology for the treatment of rosacea and acne.¹⁷ It was observed that some patients who underwent IPL treatment for facial rosacea showed improvement in their MGD and DED.¹⁷ Based on these observations, the energy levels and timing of IPL therapy were refined and modified for the treatment of MGD and DED to maximize efficacy and reduce side effects. These results have been confirmed in many studies.^{15,16,18} The effect of IPL treatment may be augmented by subsequent use of low-level light therapy (LLLT) which works by photobiomodulation on the eyelids and periorbital area.^{19,20} Both clinical parameters and cytokine levels in tears have shown changes after treatment of MGD even with IPL therapy.²¹ The underlying inflammatory pathogenesis of various forms of DED is well established.²² Evaluating and understanding the changes in these molecular factors after treatment will enhance our understanding of therapeutic effects.^{21,23} Although there is some literature regarding the effect of IPL on secreted inflammatory factors at the ocular surface,²¹ the effect of treatment on immune cells on the ocular surface is unknown.

This study is the first to evaluate the clinical outcomes and ocular surface inflammatory status based on molecular factors and immune cells after combined light therapy of IPL + LLLT with the Eye-light device in patients with recalcitrant MGD and evaporative DED. Evaluating the outcomes of this treatment will help in patient selection, decision-making, and prediction of treatment outcomes.

METHODS

Study Cohort and Clinical Parameters

This prospective interventional longitudinal study was approved by the institutional ethical committee. A total of 47 subjects (94 eyes) with chronic MGD were included in the study after providing written informed consent. Subject recruitment and sample collection procedures were conducted as per institutional guidelines and in accordance with the tenets of the Declaration of Helsinki. The clinical evaluation of MGD and DED included Ocular Surface Disease Index (OSDI), tear breakup time (TBUT), Schirmer test 1 (ST1), corneal and conjunctival staining, lid evaluation including changes such as pitting, telangiectatic vessels, evaluation and grading of MGD based on the meibomian gland expressibility score (MGS), and meibography by IDRA (SBM Sistemi Inc, Strada Torino, Italy) for meibomian gland dropout assessment²⁴ at baseline and postprocedure at 1, 3, and 6 months. The patients also underwent intraocular pressure measurement and dilated retinal evaluation.

The OSDI is a 12-item questionnaire score for assessment of symptoms related to dry eye.²⁵ TBUT was measured 3 times consecutively after fluorescein instillation using a timer, and the median value was recorded. The ST1 was performed for 5 minutes without topical anesthesia, using a sterile Schirmer test strip. Corneal and conjunctival staining

was evaluated after instillation of fluorescein dye. Meibomian glands expressibility score (MGS) was assessed by expressing meibum from 5 glands each in the nasal, middle, and temporal parts of the eyelid. Secretions were graded on a scale of 0 to 3 for each gland: 0, blocked; 1, toothpaste-like secretions; 2, cloudy secretions; and 3, clear secretions. The total score was calculated based on the number of glands multiplied by the type of meibum expressed. Maximum total score per eyelid of 45 indicates normal meibomian glands.²⁶ Meibomian gland dropout on the eyelids was assessed and graded into the percentage of dropout on meibography.⁴

Inclusion Criteria

1) MGD grade 3 and above;⁴ 2) chronic MGD of more than 6 months duration and at least 3 months of conservative treatment for MGD including warm compress, lid hygiene, antibiotic ointment, oral medications without adequate relief of symptoms or improvement in chronic MGD-related lid changes, and dry eye signs; 3) significant ocular discomfort as measured by OSDI >22; 4) features of MGD based on clinical signs and meibography >20% and <80% dropout; and 5) evaporative dry eye based on low TBUT <10 seconds and the Schirmer test >10 mm at 5 minutes.

Exclusion Criteria

Known allergy to the treatment; skin photosensitivity; active ocular infection; recent ocular surgery (less than 6 wk before); collagen vascular disease; history of procedural therapy for dry eye including punctal plugs in the eye, IPL, or thermal pulsation therapy; history of skin cancer; pigmentation in the proposed area of treatment; pregnant or lactating patients; and those with dark pigmented skin (Fitzpatrick grade >4) were excluded from treatment.²⁷

The primary end point was an improvement in OSDI from pretreatment to 3 and 6 months posttreatment. Secondary end points were changes in TBUT, MGS, and molecular and immune cell markers in tear sample and immune wash, respectively, pretreatment to posttreatment. All patients were monitored for treatment-related side effects. The plan of treatment and energy used for the IPL therapy are based on the severity of meibomian gland involvement on meibography and the skin tone graded by Fitzpatrick grading.¹⁸

Treatment Details

The combined light therapy (IPL + LLLT therapy) was performed using the Eye-light device (Espansione Marketing SPA., Bologna, Italy), which is CE Marked for the treatment of MGD. All treatments were performed with strict adherence to safety protocols as recommended by the manufacturer and existing guidelines.^{19,28,29} The IPL treatment uses xenon light (wavelength 400–1200 nm and intensity 10 J/cm² to 13 J/cm²) administered as per the MGD and the Fitzpatrick skin type grading. Patients included in the study underwent treatment of MGD with combined IPL, followed by LLLT as per published treatment recommendations.¹⁹ The patient's eyes are closed with protective opaque goggles during the IPL procedure as per the safety recommendations. No skin gel was required to be applied during this procedure with the Eye-light device. A total of 5 IPL pulses are delivered around

each eye at predetermined standard sites. The same sequence is then repeated for the other eye. The protective goggles are not required during LLLT, and the patient is advised to keep the eyes closed so that both upper and lower lids are treated. Additional packing was performed with cotton along the forehead and at the edge of the mask to avoid device-to-skin contact and prevent any inadvertent skin burns. All procedures were performed by a trained ophthalmologist, and a single treatment was performed and results assessed at the end of 3 and 6 months postprocedure.

Tear Fluid Collection

Tear fluid samples were collected, as previously described,³⁰ from a subset of study subjects (N = 9; 18 eyes) using Schirmer strips by following the Schirmer test I protocol and stored in microcentrifuge tubes at -80°C until further processing. Tear proteins were extracted from Schirmer strips by agitation in 300 μL of sterile 1xPBS for 2 hours at 4°C . The tear fluid was eluted by centrifugation and was stored in -80°C until further analyses.

Tear Soluble Factor Measurements

Simultaneous quantification of interleukin (IL)-1 α , IL-1 β , IL-4, IL-6, IL-8, IL-9, IL-10, IL-12/IL-23p40, IL-12p70, IL-13, IL-17A, IL-17F, IL-18, IL-21, IFN α , IFN γ , TNF α , CCL11/eotaxin, CCL2/MCP1, CCL5/RANTES, CXCL9/monokine induced by gamma interferon (MIG), CXCL-10/IP-10, CXCL11/I-TAC, TGF β 1, Vascular endothelial growth factor (VEGF), sICAM-1, and IgE was performed by multiplex enzyme-linked immunosorbent assay using the cytometric bead array (BD CBA Human Soluble Protein Flex Set System; BD Biosciences) on a flow cytometer (BD FACSCanto II; BD Biosciences) as previously described.³⁰ BD FACSDiva software (BD Biosciences) was used to acquire the beads and record signal intensities. The absolute analyte concentrations were measured using FCAP array version 3.0 (BD Biosciences). Similarly, the levels of Brain-derived neurotrophic factor (BDNF), IL-33, IFN β , MMP9, TIMP1, Myeloperoxidase (MPO), and Nerve growth factors (NGF) were simultaneously measured by multiplex enzyme-linked immunosorbent assay using the LEGENDplex kit (BioLegend Inc) according to manufacturer's instructions and measured on a flow cytometer (BD FACSCanto II; BD Biosciences). BD FACSDiva software (BD Biosciences) was used to acquire the beads and record signal intensities. The absolute concentration was determined based on respective standards using LEGENDplex Data Analysis Software Suite (BioLegend Inc). The absolute concentrations of these analytes were obtained using respective standards. The wetting length of the Schirmer strip and tear elution buffer volume were used to determine the dilution factor to calculate the actual concentration of the analytes in the tear fluid sample.³⁰

Ocular Surface Immune Cell Collection

Ocular surface immune cells were isolated and profiled from open eye ocular surface wash (OSW) samples as described earlier³¹ from a subset of study subjects (N = 6, 12 eyes). OSW samples were collected by a trained clinician in an outpatient clinical setting. The method of OSW for immune cell collection in brief is as follows. Sterile saline in a needleless syringe is used to wash the ocular surface gently, and the runoff fluid is collected in a sterile collection tube at the lateral canthus of the eye. Paraformaldehyde 0.05% is added to the fluid, and it is stored at 4°C .

Ocular Surface Immune Cell Phenotyping by Flow Cytometry

The proportions of the various immune cell subsets on the ocular surface of the study subjects were determined by flow cytometry-based immunophenotyping using immune cell type-specific fluorochrome-conjugated antibodies as described earlier.³¹ In brief, the fixed cells in OSW samples were centrifuged at 2000 rpm for 5 minutes at 4°C . The cell pellet was stained with antibody cocktails diluted in staining buffer (5% fetal bovine serum in 1X phosphate buffer saline, pH 7.4) by agitation (500 rpm) for 45 minutes at room temperature. Cells were washed and resuspended in 300 μL of 1X phosphate buffer saline, pH 7.4. Fluorochrome-conjugated antibodies specific for the various immune cell subtypes (neutrophils, monocytes, macrophages, eosinophils, natural killer (NK) cells, Natural Killer T (NKT) cells, T cells, and B cells) used are as follows: CD45 APC-H7 (clone 2D1), CD3 PE (clone HIT3A), CD56 PE-Cy7 (clone B159), CD19 PerCP (clone SJ25C1), CD11b BV510 (clone ICRF44), CD16 BV605 (clone 3G8), CD14 Fluorescein isothiocyanate (clone M Φ P9), and CD66b AlexaFluor 647 (clone G10F5). All fluorochrome-conjugated antibodies were purchased from BD Biosciences. Data acquisition was performed on the BD FACSLyric flow cytometer in BD FACSuite software (BD Biosciences) and analyzed using FCS Express 6 (De Novo Software). Postacquisition compensation was performed using single-stained controls. A manual gating strategy was applied for immune cell subsets identification (see Supplementary Figure, Supplemental Digital Content 1, <http://links.lww.com/ICO/B345>). Cell populations were identified and regions designated based on universal negative and fluorescence-minus-one control.

Statistical Analysis

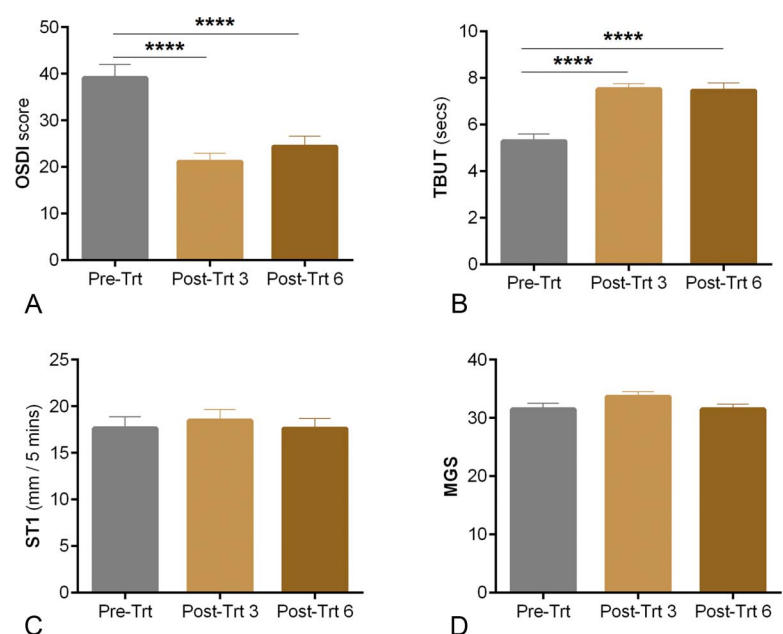
Observations are reported as mean \pm standard error of mean and represented as bar graphs. The normality of data was assessed by the Shapiro–Wilk normality test. Differences in the variables between the pretreatment and posttreatment in matched samples were analyzed using the Wilcoxon matched-pairs signed-rank test and the Friedman test with the Dunn multiple comparisons test using GraphPad Prism 8.0 (GraphPad Software, Inc, La Jolla, CA). $P < 0.05$ was considered to be statistically significant.

RESULTS

Clinical Parameters

The combined light therapy (IPL + LLLT) showed a significant improvement in clinical metrics in a majority of patients. The OSDI score was observed to be significantly ($P < 0.0001$) reduced 3 months posttreatment (mean \pm standard error of mean; 21.1 ± 1.8) and 6 months posttreatment (24.4 ± 2.2) compared with pretreatment (39.1 ± 2.8) as shown in Figure 1A. The OSDI score decreased in 95.6% subjects after treatment. Furthermore, the OSDI score decreased by more than 10 points in 68.1% of subjects and less than 10 points in 31.8% subjects posttreatment. A significant increase ($P < 0.0001$) in the tear breakup time (TBUT) was observed 3 months posttreatment (7.5 ± 0.2 s) and 6 months posttreatment (7.4 ± 0.3 s) compared with pretreatment (5.2 ± 0.3 s) (Fig. 1B). TBUT was observed to be increased in 72.3% of the eyes, did not change in 22.3% of the eyes, and decreased in 5.3% of the eyes posttreatment. As shown in Figure 1C, no significant difference was observed in ST1 values between pretreatment (17.6 ± 1.2 mm/5 min), 3 months posttreatment (18.4 ± 1.1 mm/5 min), and 6 months posttreatment (17.6 ± 1.0 mm/5 min). Although there was no significant change in the MGS posttreatment (Fig. 1D), the MGS increased in 80.8% of the eyes, did not change in 9.5% of the eyes, and decreased in 9.5% of the eyes posttreatment. The findings strongly indicate that combined light therapy improves ocular surface-related signs and symptoms in the study subjects. Although the patients in this study underwent only 1 treatment session, there was a significant improvement in symptoms and signs. None of the patients had severe discomfort during the procedure requiring discontinuation of the procedure midtherapy or any side effects during the study period.

FIGURE 1. Status of Ocular Surface Disease Index score, TBUT, ST1, and meibomian gland score in study subjects before and after 3 and 6 months posttreatment: The graphs indicate Ocular Surface Disease Index score (A), TBUT (B), ST1 values (C), and meibomian gland expressibility score (D) in study subjects before and after 3 and 6 months of IPL + LLLT treatment. N = 43, 86 eyes. Pre-Trt, pretreatment (N = 47, 94 eyes); Post-Trt 3, posttreatment 3 months (N = 47, 94 eyes); Post-Trt 6, posttreatment 6 months (N = 43, 86 eyes); bar graphs represent mean \pm SEM; **** $p < 0.0001$, the Friedman test with the Dunn multiple comparisons test. SEM, standard error of the mean. (The full color version of this figure is available at www.corneajrnl.com.)



Molecular Factors and Immune Cell Parameters

The ocular surface health status has been shown to be associated with tear inflammatory factors and local immune cells.³¹ Hence, changes in tear fluid inflammatory factors were determined in pretreatment and posttreatment tear samples. A significant reduction in tear IL-1 β , IL-17F, and MMP9 levels and MMP9/TIMP1 ratio and significant increase in IL-18 were observed in the tear fluid posttreatment compared with pretreatment (Table 1). Proportions of ocular surface immune cells were studied using OSW samples before and after combined light treatment in a subset of study subjects. Among the immune cell subsets studied, the proportion of B cells was significantly reduced in ocular wash samples collected posttreatment compared with pretreatment samples (Fig. 2). These observations suggest a decrease in the ocular surface inflammation validating the improvement in ocular surface health metrics.

DISCUSSION

Chronic MGD leading to evaporative dry eye can have a significant impact on quality of life.³² Meibomian gland inflammation with dropout or duct blockage leads to stasis of the meibum inside the glands.⁴ This can result in changes in the tear film stability and evaporative dry eye. The ocular surface and tear film are linked to the immune system by the continuous epithelium across the surface and the vascular and neural connections.³³ The loss of homeostasis is one of the key features of any kind of DED with a resultant change in the osmolarity and inflammatory damage to the ocular surface.³⁴ Multiple studies have demonstrated that the osmotic and inflammatory stress associated with dry eye increases the production of proinflammatory cytokines,

TABLE 1. Levels of Tear Soluble Factors Before and After IPL + LLLT Treatment in Study Subjects

Tear Soluble Factors Conc. (pg/mL)	Pre-Trt			Post-Trt (3 mo)			P
	Mean	SD	SEM	Mean	SD	SEM	
IL-1 α	356	370	87	346	371	87	0.580
IL-1 β	18	27	6	10	29	7	0.040
IL-4	113	213	50	99	154	36	0.687
IL-6	19	46	11	6	15	4	0.060
IL-8	1134	1345	317	673	828	195	0.142
IL-9	121	214	50	172	428	101	0.753
IL-10	41	128	30	173	389	92	0.173
IL-12/IL-23p40	2796	3864	911	2628	3956	932	0.959
IL-12p70	2	5	1	6	14	3	0.225
IL-13	11	27	6	2	7	2	0.116
IL-17A	167	451	106	118	273	64	0.463
IL-17F	81	183	43	15	38	9	0.010
IL-18	1027	1707	402	1732	1937	457	0.040
IL-21	2486	3658	862	2497	5366	1265	0.570
IL-33	170	189	44	281	456	107	0.369
IFN β	736	750	177	1278	1635	385	0.090
IFN α	3	10	2	0	0	0	0.109
IFN γ	8440	20,775	4897	30,628	71,764	16,915	0.144
TNF α	496	1390	328	569	1857	438	0.893
CCL11/Eotaxin	10	24	6	1	1	0	0.144
CCL2/MCP1	1168	1783	420	1196	2183	515	0.943
CCL5/RANTES	158	162	38	219	373	88	0.495
CXCL9/MIG	2559	4616	1088	1743	3164	746	0.229
CXCL-10/IP-10	12,822	26,001	6128	6590	10,923	2575	0.356
CXCL11/I-TAC	119	271	64	41	91	21	0.138
MMP9	190,874	397,013	93,577	32,990	39,394	9285	0.020
TIMP1	47,570	71,467	16,845	27,616	18,105	4267	1.000
MMP9/TIMP1	6	8	2	2	2	1	0.005
MPO	175,194	189,735	44,721	97,800	79,644	18,772	0.154
BDNF	194	223	52	366	611	144	0.734
NGF	16	17	4	27	45	11	0.702
TGF β 1	40	170	40	108	376	89	0.593
VEGF	506	439	103	331	333	78	0.142
sICAM-1	17,429	16,427	3872	23,164	39,048	9204	0.640
IgE	22	34	8	12	25	6	0.158

P < 0.05 was considered to be statistically significant. The Wilcoxon matched-pairs signed-rank test was performed. N = 9; 18 eyes.

Bolded values are analytes with statistical significance.

SEM, standard error of the mean.

chemokines, and matrix metalloproteinases (MMPs).^{35,36} These promote the activation of immature antigen-presenting cells which prime the T cells—CD4 helper T-cell (T_H) subtype 1 and T_H17 cell subsets.^{31,37} T cells infiltrate the ocular surface, where they secrete additional proinflammatory cytokines such as IL-17 and other proinflammatory cytokines, such as IL-1, IL-6, and TNF α .^{38,39} These have been found in the tears and ocular surface of patients with DED along with elevated levels of IL-2, IL-4, IL-5, IL-10, and MMP9.^{38–40}

There are a number of treatment modalities for MGD,⁴ including oral doxycycline; in severe MGD Doxycycline acts by inhibiting the activity of MMPs, primarily MMP9, and promoting ocular surface integrity.^{41,42} However, there is a section of patients who continue to have recalcitrant or

chronic disease despite these treatments. The recent procedural therapies for MGD, such as IPL, have shown promising results.^{43–45} Other options for procedural management of MGD are thermal pulsation therapy,¹³ combining IPL with meibomian gland expression,^{46,47} and IPL with LLLT.¹⁹

The exact mechanism of action of the IPL therapy has not yet been elucidated. The presumed action is essentially thermal, which induces an increase in temperature of the blood in larger vessels of the lid, resulting in heating the meibum in clogged glands up to its phase transition temperature, thereby improving both quality and quantity of meibomian gland secretions. Smaller telangiectatic blood vessels can get coagulated, which reduces the influx of inflammatory mediators to the eyelid and meibomian

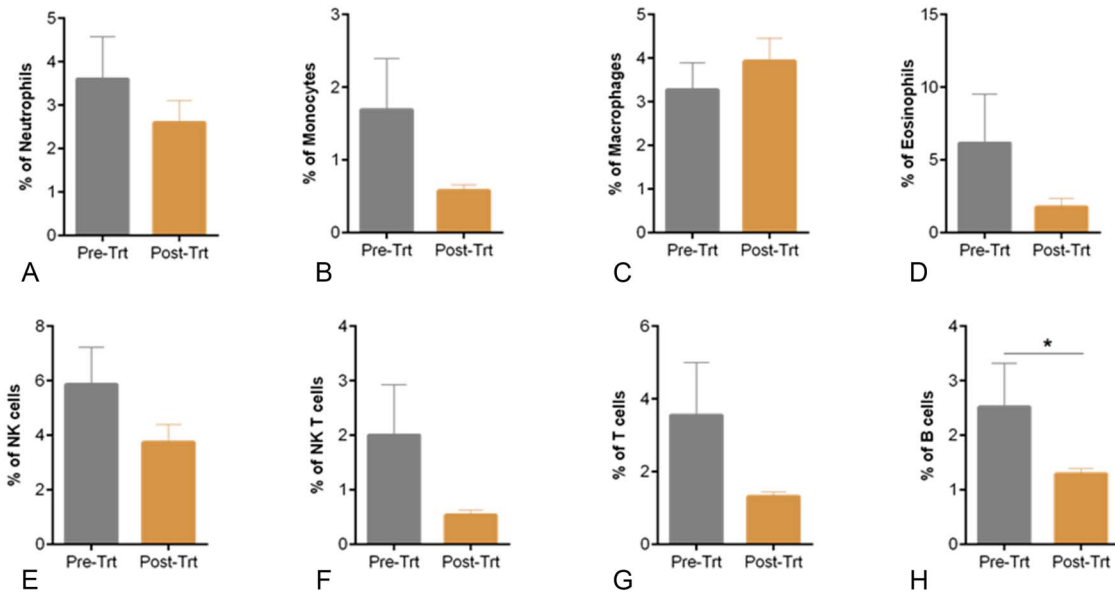


FIGURE 2. Ocular surface immune cell subset proportions in study subjects before and after treatment: (A) graph indicates the percentage of CD45⁺CD11b⁺CD16⁺CD66b⁺—neutrophils, (B) percentage of CD45⁺CD14⁺—monocytes, (C) percentage of CD45⁺CD16⁺—macrophages, (D) percentage of CD45⁺CD11b⁺CD16[−]CD66b⁺—eosinophils, (E) percentage of CD45⁺CD16⁺CD56⁺—NK cells, (F) percentage of CD45⁺CD3⁺CD16⁺CD56⁺—NKT cells, (G) percentage of CD45⁺CD3⁺—T cells, and (H) percentage of CD45⁺CD3[−]CD19⁺—B cells within the leukocyte population in OSW samples from subjects before and after 3 months of IPL+ LLLT treatment. N = 6, 12 eyes. Bar graphs represent mean ± SEM; **P* < 0.05, the Wilcoxon matched-pairs signed-rank test. SEM, standard error of the mean. (The full color version of this figure is available at www.corneajrnl.com.)

glands.⁴⁸ Inhibition of proinflammatory cytokines and increased secretion of antiinflammatory cytokines have also been demonstrated after this procedure.^{21,49} By contrast, LLLT is believed to act by a process called photobiomodulation,¹⁹ which uses LED light of near-infrared wavelength. LLLT has been found to affect wound healing, pain modulation, and normalization of cell function.^{20,50}

The current study demonstrated a significant improvement in the symptoms and signs of MGD and evaporative dry eye in a majority of patients when the combined IPL + LLLT therapy was applied. LLLT could have an additive effect along with the IPL therapy, especially over the upper lids where IPL is not performed. The improvements reported here are similar to those reported with IPL in previous studies.^{16,48,51,52} Ocular surface symptoms were reduced significantly after IPL therapy in studies,^{29,51} and this finding was corroborated in our study with around 95% of patients showing improved symptomatology as measured by OSDI. A significant increase (*P* < 0.0001) in the TBUT was observed posttreatment with combined light therapy in 72.3% of the eyes along with other features such as meibomian gland secretions, expressibility, and telangiectasia. This was similar to results in studies on the effect of IPL alone^{15,29} and combined IPL with LLLT.¹⁹ The slight increase in the OSDI score in some patients at 6 months could suggest the need for repeat IPL sessions for an additive effect. IPL therapy has been shown to reduce both symptoms and signs of evaporative DED and can also be useful in mixed type of DED with significant MGD.^{18,46,53}

As inflammation is key to the etiopathogenesis of the ocular surface damage in dry eye, a reduction in inflammation

would be important in achieving a good treatment outcome. Hence, it is possible that for a beneficial effect, IPL would reduce the ocular surface inflammation as well.⁴⁸ To further qualify and quantify treatment outcomes after combined light therapy, we evaluated the change in molecular factors and immune cells on the ocular surface pretreatment and posttreatment and correlated these with changes in clinical parameters. There are very few studies that have evaluated this aspect of inflammatory markers and cellular change after IPL^{21,54} and no studies using both IPL and LLLT. The antiinflammatory effect of IPL is confirmed by the significant reduction in levels of tear inflammatory markers IL-17A and IL-6 in patients with MGD.²¹ However, there are a number of other inflammatory markers, and the dysregulation of which is associated with ocular surface inflammation and DED. These need to be evaluated as well to get a broad understanding of the mechanism of action of IPL. In our study, we found alterations in IL-1β, IL-17F, MMP9, MMP9/TIMP1 ratio, and IL-6 which correlated well with the reduction in ocular discomfort and improvement in TBUT after treatment. These dysregulated tear factors have been shown to be significantly associated with DED signs and symptoms.^{30,55} This explains the significant improvement in ocular symptomatology in patients after combined light therapy even in patients who did not show a large change in their clinical parameters.

The cumulative decrease in the levels of inflammatory factors IL-4, IL-8, IL-12/IL-23p40, IL-17A, eotaxin, MIG, IP-10, I-TAC, TIMP1, MPO, VEGF, and IgE which are associated with ocular surface inflammation after a single-treatment session will be beneficial to the ocular surface

homeostasis. Because dysregulation of molecular factors plays an important role in DED pathogenesis, the increase in antiinflammatory factors, such as IL-10, TGF β 1, and IFN β , after combined light therapy treatment would also be beneficial. Alteration in the levels of TGF β after IPL has been found in a previous study as well.²¹ TGF β has been shown to prevent migration of T cells to the conjunctiva and suppress NK cells.^{56,57} This has been demonstrated in our study as well, where the increase in TGF β correlates with the decreasing proportions of NK cells, NKT cells, and T cells after therapy. The increase in BDNF and NGF which are considered to be antinociceptive factors⁵⁸ could also contribute to decrease in ocular pain after treatment.

The preprocedural treatment with various topical and oral medications for MGD could be a confounding factor in the assessment of treatment outcomes. However, all patients included had shown a poor response to medical therapy before inclusion in the study. Because the IPL and LLLT are performed at the same sitting, it is not possible to individualize the beneficial effects of each treatment; however, it may give more lasting effects which can be evaluated in long-term studies. Long-term outcomes and cumulative effects of multiple sessions have not been addressed in this study. This study compares the baseline status of the subjects undergoing the procedure and the treatment effects on follow-up. There is no separate control arm included in this study for comparison. However, the same group of subjects was included pretherapy and posttherapy, and their tests and samples were repeated at pretime points and posttime points. They therefore act as matched subject-specific controls. A mock treatment arm and longer follow-ups with multiple treatments are limitations of the study and will be followed up in future studies.

The intense pulse light therapy has shown promising results for the treatment of MGD in both evaporative dry eye and mixed type of dry eye. This is the first study of combined light therapy (IPL + LLLT) in which changes in clinical features have been correlated with molecular and immune factors in an attempt to elucidate the mechanism of action in DED. Although adverse events, such as skin pigmentation and blistering, have been documented in the literature, we did not encounter any of the above in our study. Stringent care with adequate shielding of the eyes as required, extra padding along the LLLT mask to avoid unnecessary skin contact, and clear selection of subjects, especially regarding skin tone are key to safe outcomes. The combined procedure could have a dual benefit of improving meibum quality and stimulating meibum secretions. Our study showed good treatment outcomes across the clinical parameters and a reduction in ocular surface inflammation as measured by the changes in molecular and cellular factors.

REFERENCES

- Korb DR, Blackie CA. Meibomian gland diagnostic expressibility: correlation with dry eye symptoms and gland location. *Cornea*. 2008; 27:1142–1147.
- Lemp MA, Crews LA, Bron AJ, et al. Distribution of aqueous-deficient and evaporative dry eye in a clinic-based patient cohort: a retrospective study. *Cornea*. 2012;31:472–478.
- Nelson JD, Shimazaki J, Benitez-del-Castillo JM, et al. The international workshop on meibomian gland dysfunction: report of the definition and classification subcommittee. *Invest Ophthalmol Vis Sci*. 2011;52: 1930–1937.
- Nichols KK, Foulks GN, Bron AJ, et al. The international workshop on meibomian gland dysfunction: executive summary. *Invest Ophthalmol Vis Sci*. 2011;52:1922–1929.
- Suzuki T. Meibomitis-related keratoconjunctivitis: implications and clinical significance of meibomian gland inflammation. *Cornea*. 2012; 31(suppl 1):S41–S44.
- Suzuki T, Kinoshita S. Meibomitis-related keratoconjunctivitis in childhood and adolescence. *Am J Ophthalmol*. 2007;144:160–161.
- Suzuki T. Inflamed obstructive meibomian gland dysfunction causes ocular surface inflammation. *Invest Ophthalmol Vis Sci*. 2018;59: DES94–DES101.
- Uchino M, Schaumberg DA. Dry eye disease: impact on quality of life and vision. *Curr Ophthalmol Rep*. 2013;1:51–57.
- Olson MC, Korb DR, Greiner JV. Increase in tear film lipid layer thickness following treatment with warm compresses in patients with meibomian gland dysfunction. *Eye Contact Lens*. 2003;29:96–99.
- Geerling G, Tauber J, Baudouin C, et al. The international workshop on meibomian gland dysfunction: report of the subcommittee on management and treatment of meibomian gland dysfunction. *Invest Ophthalmol Vis Sci*. 2011;52:2050–2064.
- Korb DR, Blackie CA, Finnemore VM, et al. Effect of using a combination of lid wipes, eye drops, and omega-3 supplements on meibomian gland functionality in patients with lipid deficient/evaporative dry eye. *Cornea*. 2015;34:407–412.
- Kheirkhah A, Kobashi H, Girgis J, et al. A randomized, sham-controlled trial of intraductal meibomian gland probing with or without topical antibiotic/steroid for obstructive meibomian gland dysfunction. *Ocul Surf*. 2020;18:852–856.
- Blackie CA, Carlson AN, Korb DR. Treatment for meibomian gland dysfunction and dry eye symptoms with a single-dose vectored thermal pulsation: a review. *Curr Opin Ophthalmol*. 2015;26:306–313.
- Tauber J. A 6-week, prospective, randomized, single-masked study of lifitegrast ophthalmic solution 5% versus thermal pulsation procedure for treatment of inflammatory meibomian gland dysfunction. *Cornea*. 2020; 39:403–407.
- Toyos R, McGill W, Briscoe D. Intense pulsed light treatment for dry eye disease due to meibomian gland dysfunction; a 3-year retrospective study. *Photomed Laser Surg*. 2015;33:41–46.
- Dell SJ, Gaster RN, Barbarino SC, et al. Prospective evaluation of intense pulsed light and meibomian gland expression efficacy on relieving signs and symptoms of dry eye disease due to meibomian gland dysfunction. *Clin Ophthalmol*. 2017;11:817–827.
- Papageorgiou P, Clayton W, Norwood S, et al. Treatment of rosacea with intense pulsed light: significant improvement and long-lasting results. *Br J Dermatol*. 2008;159:628–632.
- Craig JP, Chen YH, Turnbull PR. Prospective trial of intense pulsed light for the treatment of meibomian gland dysfunction. *Invest Ophthalmol Vis Sci*. 2015;56:1965–1970.
- Stoncipher K, Abell TG, Chotiner B, et al. Combined low level light therapy and intense pulsed light therapy for the treatment of meibomian gland dysfunction. *Clin Ophthalmol*. 2019;13:993–999.
- Kim WS, Calderhead RG. Is light-emitting diode phototherapy (LED-LLLT) really effective? *Laser Ther*. 2011;20:205–215.
- Liu R, Rong B, Tu P, et al. Analysis of cytokine levels in tears and clinical correlations after intense pulsed light treating meibomian gland dysfunction. *Am J Ophthalmol*. 2017;183:81–90.
- Pflugfelder SC. Antiinflammatory therapy for dry eye. *Am J Ophthalmol*. 2004;137:337–342.
- Massingale ML, Li X, Vallabhajosyula M, et al. Analysis of inflammatory cytokines in the tears of dry eye patients. *Cornea*. 2009;28: 1023–1027.
- Robin M, Liang H, Rabut G, et al. The role of meibography in the diagnosis of meibomian gland dysfunction in ocular surface diseases. *Transl Vis Sci Technol*. 2019;8:6.
- Schiffman RM, Christianson MD, Jacobsen G, et al. Reliability and validity of the ocular surface disease index. *Arch Ophthalmol*. 2000;118: 615–621.
- Lane SS, DuBiner HB, Epstein RJ, et al. A new system, the LipiFlow, for the treatment of meibomian gland dysfunction. *Cornea*. 2012;31: 396–404.

27. Thaysen-Petersen D, Erlendsson AM, Nash JF, et al. Side effects from intense pulsed light: importance of skin pigmentation, fluence level and ultraviolet radiation-A randomized controlled trial. *Lasers Surg Med.* 2017;49:88–96.
28. Toyos R, Toyos M, Willcox J, et al. Evaluation of the safety and efficacy of intense pulsed light treatment with meibomian gland expression of the upper eyelids for dry eye disease. *Photobiomodul Photomed Laser Surg.* 2019;37:527–531.
29. Jiang X, Lv H, Song H, et al. Evaluation of the safety and effectiveness of intense pulsed light in the treatment of meibomian gland dysfunction. *J Ophthalmol.* 2016;2016:1910694.
30. Khamar P, Nair AP, Shetty R, et al. Dysregulated tear fluid nociception-associated factors, corneal dendritic cell density, and vitamin D levels in evaporative dry eye. *Invest Ophthalmol Vis Sci.* 2019;60:2532–2542.
31. Nair AP, D'Souza S, Shetty R, et al. Altered ocular surface immune cell profile in patients with dry eye disease. *Ocul Surf.* 2021;21:96–106.
32. Craig JP, Nelson JD, Azar DT, et al. TFOS DEWS II report executive summary. *Ocul Surf.* 2017;15:802–812.
33. Gipson IK. The ocular surface: the challenge to enable and protect vision: the Friedenwald lecture. *Invest Ophthalmol Vis Sci.* 2007;48:43901–43908.
34. Craig JP, Nichols KK, Akpek EK, et al. TFOS DEWS II definition and classification report. *Ocul Surf.* 2017;15:276–283.
35. Luo L, Li DQ, Corrales RM, et al. Hyperosmolar saline is a proinflammatory stress on the mouse ocular surface. *Eye Contact Lens.* 2005;31:186–193.
36. Li DQ, Luo L, Chen Z, et al. JNK and ERK MAP kinases mediate induction of IL-1beta, TNF-alpha and IL-8 following hyperosmolar stress in human limbal epithelial cells. *Exp Eye Res.* 2006;82:588–596.
37. El Annan J, Chauhan SK, Ecoiffier T, et al. Characterization of effector T cells in dry eye disease. *Invest Ophthalmol Vis Sci.* 2009;50:3802–3807.
38. Solomon A, Dursun D, Liu Z, et al. Pro- and anti-inflammatory forms of interleukin-1 in the tear fluid and conjunctiva of patients with dry-eye disease. *Invest Ophthalmol Vis Sci.* 2001;42:2283–2292.
39. Enriquez-de-Salamanca A, Castellanos E, Stern ME, et al. Tear cytokine and chemokine analysis and clinical correlations in evaporative-type dry eye disease. *Mol Vis.* 2010;16:862–873.
40. Na KS, Mok JW, Kim JY, et al. Correlations between tear cytokines, chemokines, and soluble receptors and clinical severity of dry eye disease. *Invest Ophthalmol Vis Sci.* 2012;53:5443–5450.
41. Beardsley RM, De Paiva CS, Power DF, et al. Desiccating stress decreases apical corneal epithelial cell size: modulation by the metalloproteinase inhibitor doxycycline. *Cornea.* 2008;27:935–940.
42. Stevenson W, Chauhan SK, Dana R. Dry eye disease: an immune-mediated ocular surface disorder. *Arch Ophthalmol.* 2012;130:90–100.
43. Guilloto Caballero S, Garcia Madrona JL, Colmenero Reina E. Effect of pulsed laser light in patients with dry eye syndrome. *Arch Soc Esp Ophthalmol.* 2017;92:509–515.
44. Yin Y, Liu N, Gong L, et al. Changes in the meibomian gland after exposure to intense pulsed light in meibomian gland dysfunction (MGD) patients. *Curr Eye Res.* 2018;43:308–313.
45. Albietz JM, Schmid KL. Intense pulsed light treatment and meibomian gland expression for moderate to advanced meibomian gland dysfunction. *Clin Exp Optom.* 2018;101:23–33.
46. Vegunta S, Patel D, Shen JF. Combination therapy of intense pulsed light therapy and meibomian gland expression (IPL/MGX) can improve dry eye symptoms and meibomian gland function in patients with refractory dry eye: a retrospective analysis. *Cornea.* 2016;35:318–322.
47. Rong B, Tang Y, Tu P, et al. Intense pulsed light applied directly on eyelids combined with meibomian gland expression to treat meibomian gland dysfunction. *Photomed Laser Surg.* 2018;36:326–332.
48. Dell SJ. Intense pulsed light for evaporative dry eye disease. *Clin Ophthalmol.* 2017;11:1167–1173.
49. Giannaccare G, Taroni L, Senni C, et al. Intense pulsed light therapy in the treatment of meibomian gland dysfunction: current perspectives. *Clin Optom (Auckl).* 2019;11:113–126.
50. Avci P, Gupta A, Sadasivam M, et al. Low-level laser (light) therapy (LLLT) in skin: stimulating, healing, restoring. *Semin Cutan Med Surg.* 2013;32:41–52.
51. Arita R, Fukuoka S, Morishige N. Therapeutic efficacy of intense pulsed light in patients with refractory meibomian gland dysfunction. *Ocul Surf.* 2019;17:104–110.
52. Rong B, Tu P, Tang Y, et al. Evaluation of short-term effect of intense pulsed light combined with meibomian gland expression in the treatment of meibomian gland dysfunction [in Chinese]. *Zhonghua Yan Ke Za Zhi.* 2017;53:675–681.
53. Gupta PK, Vora GK, Matossian C, et al. Outcomes of intense pulsed light therapy for treatment of evaporative dry eye disease. *Can J Ophthalmol.* 2016;51:249–253.
54. Choi M, Han SJ, Ji YW, et al. Meibum expressibility improvement as a therapeutic target of intense pulsed light treatment in meibomian gland dysfunction and its association with tear inflammatory cytokines. *Sci Rep.* 2019;9:7648.
55. De Paiva CS, Chotikavanich S, Pangeliman SB, et al. IL-17 disrupts corneal barrier following desiccating stress. *Mucosal Immunol.* 2009;2:243–253.
56. Huang J, Luo X, Lu J, et al. IPL irradiation rejuvenates skin collagen via the bidirectional regulation of MMP-1 and TGF-beta1 mediated by MAPKs in fibroblasts. *Lasers Med Sci.* 2011;26:381–387.
57. De Paiva CS, Volpe EA, Gandhi NB, et al. Disruption of TGF-beta signaling improves ocular surface epithelial disease in experimental autoimmune keratoconjunctivitis sicca. *PLoS One.* 2011;6:e29017.
58. Marcol W, Kotulska K, Larysz-Brysz M, et al. BDNF contributes to animal model neuropathic pain after peripheral nerve transection. *Neurosurg Rev.* 2007;30:235–243; discussion 43.