

**XII SYMPOSIUM OF THE ANTERIOR SEGMENT**

28 th September 2018

**Granada**

**SEO'18**

# Solutions for the treatment of evaporative dry eye

Directors:

Prof. José Manuel Benítez del Castillo

Dr. Miguel Ángel Pérez Silguero

**SKYMED** 

[www.skymed.co.il](http://www.skymed.co.il) [tzah@skymed.co.il](mailto:tzah@skymed.co.il) 050-7999878 nx

## Directors

### **Prof. José Manuel Benítez del Castillo**

Professor of Ophthalmology at the Complutense University of Madrid. Head of Ophthalmology Section. Clinical Hospital San Carlos. Madrid.

### **Dr. Miguel Ángel Pérez Silguero**

Head of the Ophthalmology Service of La Paloma Polyclinic Hospital. Las Palmas de Gran Canaria.

## Presentations

**Evaporative dry eye Prof. José Manuel Benítez del Castillo**

**Diagnosis and MGD treatment with Eye Light platform Dr. Ioana Romero**

**Treatment of dry eye with pulsed light, prior to refractive surgery Dr. Ludger Hanneken**

**Morphological evolution of Meibomian glands post-treatment with EyeLight platform Dr. Miguel Ángel Pérez Silguero**

**Current evaluation of refractive surgery in patients with dry eye Dr. Federico Alonso Aliste**

## INTRODUCTION

The Granada Congress Center hosted the 94th Congress of the Spanish Society of Ophthalmology, in which the XII Symposium of Anterior Segment was held on September 28, sponsored by Topcon and dedicated to "Solutions for the treatment of evaporative dry eye".

Moderated by Prof. José Manuel Benítez del Castillo and Dr. Miguel Ángel Pérez Silguero, it was the first who opened the turn of interventions to introduce the topic of study, highlighting that dry eye is the most frequent

ocular pathology, for which there is a broad arsenal of drugs and procedures that are effective in most cases. Among them, the combined use of intense pulsed light (IPL) and photobiomodulation has proved to be very useful to treat this disease when the first line of therapy does not achieve the resolution of symptoms, as expressed by some of the speakers, who presented their clinical experience with this technology. Of particular interest is the need to treat the problem preoperatively in patients who are going to undergo refractive surgery, cataracts and intraocular lenses.

## PAPERS

### Evaporative dry eye

#### **Prof. José Manuel Benítez del Castillo**

Prof. Benítez del Castillo, Professor of Ophthalmology at the Complutense University of Madrid and Head of the Ophthalmology Section of the San Carlos Clinical Hospital (Madrid), began his speech with the definition of TFOS DEWS II, according to which the dry eye is a "Multifactorial disease of the ocular surface, characterized by a loss of the homeostasis of the tear film and accompanied by ocular symptoms, in which instability of the tear film, hyperosmolarity, injury and inflammation of the ocular surface and sensorineural abnormalities they play an etiological role. "

It is the most frequent ocular pathology, with a prevalence between 5.7% and 9.8% in women over 55 years of age and 3.5% in men of the same age group.



About the tear film, he explained that it is formed by three overlapping layers, but it is the lipid layer -the outer one- that is involved in the dry eye and whose most important function is to avoid the accumulation of the aqueous gel.

Although there are two types of dry eye, the evaporative and the hyposecretor, the speaker commented that both end up mixing and that the boundary between the two categories is unclear. However, it is considered that the evaporative dry eye is the most frequent and that 88.5% of all cases are at least partially evaporative.

He then referred to meibomian gland dysfunction (MGD), a highly prevalent disorder that affects the Asian population more than the Caucasian population.

The diagnosis of MGD is carried out by external examination. Attention must be paid to the general appearance, the spontaneous flicker, the characteristics of the skin, the facial asymmetry, the palpebral pockets and the laxity; but in the opinion of the presenter, expressing the eyelid is usually sufficient to confirm it. He explained the procedure he uses in his practice is to perform a BUT to confirm the presence of dry eye and, subsequently, a Schirmer test. If this test gives a result greater than 10, with abnormal BUT and symptoms, MGD can be confirmed.

Regarding recommendations to patients with evaporative dry eye, he mentioned among others, to avoid drying medications, avoid convection currents, avoid smoke and pollution, use humidifiers, use correctly

visualization screens, hydration, optical correction or blinking exercises

To reduce tear evaporation, he commented on the usefulness of tears with lipids -with and without preservatives-, as well as ointments without preservatives. Likewise, he emphasized not to forget palpebral heating, suggesting that moist heat seems to be better than dry heat, and the use of devices for cleaning and microexfoliation of the eyelid margin.

He continued to talk about pulsed light (IPL), a procedure whose efficacy in dry eyes was discovered by dermatologists when treating telangiectasias in patients with rosacea. In the opinion of Prof. Benitez del Castillo, there is clear evidence that IPL works as a treatment for MGD.

In his conclusions, he emphasized that the evaporative is the most frequent type of dry eye, that its diagnosis is accessible to the general ophthalmologist and that it has specific treatments different from those applicable to dry eye acuo-deficient.

*"There is clear evidence that intense pulsed light works as a treatment for Meibomian gland dysfunction"*

## Diagnosis and MGD treatment with EyeLight platform

### Dr. Ioana Romero

"The existence of many treatments for the same pathology means that none of them is totally effective, which forces us to try different treatments one after another ". This is how Dr. Ioana Romero, of the Oculoplasty Unit of the Bilbao Comprehensive Ophthalmological Center and Resident Tutor of Ophthalmology at the Galdakao-Usansolo Hospital (Vizcaya) began her intervention.

The choice of the treatment depends on the severity of the dry eye and, in her opinion, it is essential to treat the first level well so that the disease does not evolve to the following levels. For this first level, patient education, artificial tears in different forms and palpebral treatment are available.

In the second level, anti-inflammatories, oral tetracyclines, secretagogues and glasses with humidity chambers are used. For the third, serum vs platelet-enriched plasma, contact lenses and lacrimal dot occlusion are used, while systemic antiinflammatories and surgery are used for the fourth.

Focusing on the first level of treatment, she explained that patient education would be based on environmental and food modifications. Regarding artificial tears, she mentioned its availability in multiple forms - mono and disaccharides, polysaccharides, mucopolysaccharides, lipids -; and regarding the palpebral treatment, she pointed out that it can be done with gels, foams or wipes, as well as with extracts such as the tea tree, grapefruit, etc.



She also mentioned new direct palpebral treatments on the Meibomian gland (cleaning, local heat and photobiomodulation) and indirect treatments on said gland, such as intense pulsed light (IPL / OPE).

Photobiomodulation is characterized by having an optimized wavelength to activate the mitochondria and increase the production of ATP, which translates into an endogenous heat that penetrates the Meibomian gland, liquefies the fat and improves its expression and diffusion in the ocular surface, thus restoring the normal functioning of the gland.



She mentioned OPE (Optimal Power Energy) as a technology consisting of a modification of the IPL with greater control of the emission of heat that avoids the need to use gels for its application. The pulsed light is captured by the chromophores present in the hemoglobin of the dilated vessels at the eyelid margin, which decreases its size. In addition, this treatment stimulates the neurotransmitters of the glands to increase the flow of lipid. "What we do with the IPL," she said, "is to close those small vessels, preventing proinflammatory substances from reaching them, and we carry out a mechanical opening of the Meibomian gland. Added this to the endogenous heat produced by the photobiomodulation, we improve the functioning of the gland".

She then described the experience in her Unit since she started using the EyeLight platform in December 2017, with a series of 36 patients treated and with a maximum follow-up of 6 months.

Eleven men and 25 women were classified according to the severity of Meibomian gland dysfunction, questioned about their symptoms - troubles, discomfort, blurred vision, lacrimation- and examined for signs such as ocular hyperemia and redness of the eyelid margin. 42% of the patients presented a level 4 of severity, because EyeLight was not offered as the first therapeutic choice, and several patients had associated pathologies such as Sjögren's syndrome, acudeficient dry eye, ectopion and rosacea.

After treatment, up to 91% of the patients experienced symptomatic improvement. Specifically, 91% showed improvement in their discomfort, 91% in their blurred vision and 86.1% in tearing. Likewise, hyperemia improved in 94.4% of patients treated with EyeLight, and redness of the eyelid margin was also improved in 94.4%.

In her conclusions, Dr. Romero explained that it is necessary to understand well the different weapons available to treat dry eye in order to offer the most appropriate treatment to each patient according to their degree of severity.

She also repeated that if the first level of severity of the ocular surface is adequately treated, it will be more difficult to worsen other levels.

Finally, she stressed that the most important thing is to explain well to the patient the situation of chronicity and the real objectives that can be achieved with the treatment.

*"It is necessary to understand well the different weapons available to treat dry eye in order to offer the most appropriate treatment to each patient according to their degree of severity."*

## Treatment of dry eye with pulsed light, prior to refractive surgery

### Dr. Ludger Hanneken

Dr. Ludger Hanneken, refractive surgeon, founder and medical director of Vallmedic Vision & Aesthetic (Andorra), stressed first that dry eye is a hot topic in current ophthalmology. In his presentation he pointed out that this disease can have a negative impact on vision, especially in cataract surgery and refractive surgery, as well as playing an important role in the selection of intraocular lenses (IOL).

As Dr. Hanneken explained, dry eye has become an epidemic, due to drugs, pollution and the excessive use of digital screens, among other factors.

He highlighted the results of the PHACO study, in which 60% of cataract surgery patients presented a very short NIBUT and approximately half showed staining in the center of the cornea, which means that they are subjects with dry eyes who should receive treatment before surgery.

He also mentioned another study by the American Society of Refractive Surgery and Cataract (ASCRS), whose results showed that 70% of the 1,500 members of this scientific society were unaware of the dry eye treatment algorithms and the dysfunction of the Meibomian glands..

On the other hand, it has been estimated that only 22.1% of patients with cataracts knew that they had dry eyes. In the opinion of the presenter, probably most of them had not been informed that they were affected by this disease.



He then showed that the optic aspects of the tear film are very important for refractive surgery, cataracts and multifocal lenses. It has been observed that the thickness of the cornea of patients with dry eye is significantly reduced compared to that of people of the same age and sex.

In addition, the hyperosmolarity of the tear causes a great variability in the keratometric tests. In this sense, not treating the dry eye before surgery may result in inaccurate keratometric measurements, as well as erroneous wavefront values and topographies.

Other consequences can be an incorrect IOL calculation, incorrect inclusion / exclusion for the selection of multifocal IOLs,

patients dissatisfied due to residual refractive error, impaired visual quality with multifocal IOL and less tolerance to optical phenomena.

The vast majority of patients with dry eye have dysfunction of Meibomian glands (MGD), which must be diagnosed before surgery. For this there are several questionnaires and tests, although not all can be carried out in the daily clinic, so Dr. Hanneken explained that in each patient that is going to be operated on cataract or refractive surgery, he uses the available OSDI and SPEED questionnaires online and tracking is done by mobile phone. This procedure, he said, saves time, travel, space and personnel; facilitates monitoring, and shows an automatic calculation of the results of the aforementioned questionnaires.

Such results determine if the patient will need to undergo other tests to confirm the diagnosis of evaporative dry eye and, in such case, receive treatment.

In patients with blepharitis and blocked orifices, Clean Lid is used - heat with infrared light, debridement of the edge of the eyelid and manual treatment of the Meibomian glands- or treatment with intense pulsed light (IPL) and photobiomodulation.

In cases of patients without blepharitis and without blocked orifices, IPL and photobiomodulation are used.

In summary, Dr. Hanneken stressed that for the implantation of a multifocal lens it is especially important that the patient has a good tear film.

Likewise, the IPL combined with the photobiomodulation, can improve the quality of the tear film in case of MGD. In addition, optimizing the tear film also improves the tolerance to multifocal IOL.

Therefore, he concluded that "in cases of confirmed dry eye, it is advisable to treat the disease before refractive surgery and surgery with IOL, especially multifocal IOL".

*"In cases of confirmed dry eye, it is advisable to treat the disease before refractive surgery and surgery with IOL, especially multifocal IOL."*

## Morphological evolution of Meibomian glands post-treatment with EyeLight platform

**Dr. Miguel Ángel Pérez Silguero**

As a refractive surgeon, Dr. Pérez Silguero, head of the Ophthalmology Service at the La Paloma Polyclinic Hospital (Las Palmas de Gran Canaria), explained that his team tries to carry out the best possible preoperative work, achieving emmetropia in the largest part of cases before surgery. However, one should be aware that the patient will not be satisfied after the operation if he has a dry eye.

"It is widely contrasted that intense pulsed light (IPL) works and the TFOS DEWS II guide includes it as a second step in the treatment of dry eye, in case the first step, consisting of hygiene of the eyelids, use of lubricants and hot compresses, does not work," he commented, underlining that it is an easy procedure to use during consultation at the same slit lamp.

The subject of his paper focused on the research carried out to find out why IPL is effective and what microscopic and macroscopic changes are observed in Meibomian glands after treatment.

He explained that these glands are found in the posterior lamella and that each one is made up of multiple secretory acini that contain meibocitos, lateral ductulos, a central duct and a terminal excretory duct that opens in the posterior margin of the eyelid, **being its greater number in the upper eyelid.**

When an obstruction of the terminal duct occurs due to a hyperkeratinization of the ductal epithelium and an increase in the viscosity of the sebaceous secretion, a plug is formed, so that the secretion returns to the inside of the gland. "This leads to an increase in acini,



loss of meibocitos and deformity of the gland, with an increase in the evaporation of the tear and hyperosmolarity and, consequently, dry eye," said Dr. Pérez Silguero. However, it is a reversible situation. "

On this point, he recalled that the dry eye is diagnosed if there is a hyperosmolarity higher than 308 mOsm / l, but that many artificial tears that are used are hyperosmolar, which is counterproductive for the treatment.

Regarding the microscopic changes in the Meibomian glands, the speaker explained that these are early changes. Recent investigations<sup>4</sup> have observed the total deformation of the secretory acini, but after three sessions of treatment with IPL they return to normal.

Unlike the microscopic ones, the macroscopic changes are delayed, according to his team,

using Keratograph and the Jenvis test, which allows assess the amount of Meibomian glands, their length, distortion, inflammation, atrophy, etc.

The speaker presented a series of clinical cases treated in his Service with the Eye Light in which macroscopic changes are observed when comparing the glands at the beginning and after three months of treatment.

On this point, he referred to a hypothesis that tries to explain why these glands, when destroyed, can grow back thanks to the treatment with IPL.

According to a study by Parfitt and Lewis<sup>2</sup>, stem cells are found in the ductal epithelium of glandular acini. When the acini is very deformed, the stem cells can not enter, but when its size decreases after treatment, these cells can penetrate and regeneration occurs.

A new<sup>3</sup> work by Hwang and Parfitt reveals that this requires a meibocyte receptor called PPAR $\gamma$ ,

while an Asian<sup>4</sup> research group has observed that patients who have undergone hematopoietic stem cell transplant experience the same after two months, a complete regeneration of Meibomian glands.

In summary, Dr. Pérez Silguero highlighted that the vast majority of patients with dry eye improve thanks to the combined treatment of IPL plus photobiomodulation. "We started to have arguments to fight against a very frequent and despised disease," he concluded, "but we still have a long way to go."

*"We started to have arguments to fight against a very frequent and despised disease, but we still have a long way to go"*

## Current evaluation of refractive surgery in patients with dry eye

### Dr. Federico Alonso Aliste

In the last presentation of the session, Dr. Alonso Aliste, founder and medical director of Tecnolaser Clinic Vision (Seville), stressed the importance of dry eye in those patients who are going to undergo refractive surgery, and stressed in the first place that those who use screens, computers, ipads, etc for a long time suffer more eye discomfort than those who use them for a short time, although both can produce tears in normal ranges. However, the former present greater alterations of the Meibomian glands, which suggests that the dysfunction of said glands is actually responsible for the symptoms and severity of dry eye in these patients.

Throughout his speech he emphasized what evidence-based medicine indicates in relation to the assessment of dry eye and its treatment before and after surgery, showing the levels of evidence and the degrees of recommendation of the different procedures evaluated.

He reviewed the causes of dry eye after LASIK surgery, underlining that it is of multifactorial origin, and that the intervention can contribute to the disease through multiple mechanisms. Among them, the one with the highest degree of evidence is the use of topical eye drops, which together with any eye surgery, can contribute to the epitheliopathy. He also stressed that patients with preexisting Meibomian gland dysfunction may experience a worsening of dry eye symptoms.

"After LASIK surgery, he added, the sensitivity of both the cornea and the conjunctiva decreases. It also leads to alteration in the TMS-BUT until the third month after the intervention and to a decrease in the rate of blinking, which entails loss of visual quality up to one year after surgery."

In relation to evaluation and preoperative management, it has been shown that patients who receive dry eye treatment before surgery reduce their symptoms after surgery. It has been seen, on the other hand,



that the incidence of the disease after the operation is greater in patients with a history of allergy and, according to Dr. Alonso Aliste showed -with a medium grade of recommendation- it is preferable to avoid Sjögren syndrome surgery and increase caution in patients with diabetes.

Likewise, although with a lower level of evidence, it has been observed that advanced age, female sex and East Asian ethnicity are predisposing factors, as well as the history of use of contact lenses, intolerance to these and high myopia.

Regarding recommendations, treatment with topical cyclosporin A is recommended to those patients with dry eye who are going to undergo LASIK surgery, as well as urging smoking cessation, taking into account the history of blepharoplasty and the possible risk of neuropathic pain. In people with migraines, trigeminal neuralgia, fibromyalgia, allodynia and herpes zoster. It has also been observed that traditional tests are useful to detect preoperative dry eye as a risk factor for chronic disease after surgery, that the surgeon can check the corneal sensitivity if necessary and that the tear osmolarity tests are very useful before of refractive surgery.

Regarding the surgical considerations, the speaker pointed out that the Femto LASIK, in comparison with SMILE, is associated with much more serious dry eye symptoms. The available evidence also shows that the position of the LASIK hinge has a minimal effect on the severity of the dry eye after surgery and that there are no significant differences in the symptoms or function of the tear between the microkeratome and laser procedures. femtosecond.

In the final section of his speech, Dr. Alonso Aliste referred to the preoperative and postoperative management of dry eye. On the first one, he highlighted the treatment with cyclosporin until the resolution of symptoms. If after 6 months of treatment persist and the Schirmer test is <5 mm, surgery should be ruled out. The postoperative treatment has a large arsenal. First, he cited artificial tears, preferably free of preservatives. If there is dysfunction of the Meibomian glands, palpebral hygiene should be carried out and nutritional supplements, topical azithromycin or doxycycline should be used.

Oral antibiotics -tetracyclines, macrolides, azithromycin- and treatment of the lacrimal punctures are also recommended, whose affected patients may benefit from topical cyclosporin A, although anti-inflammatory agents should be prescribed several weeks before to reduce the inflammation of the ocular surface.

The presenter also mentioned as effective topical autologous serum, topical cyclosporin A, topical steroids and nonsteroidal antiinflammatory drops, eyelid heating therapy, thermal pulse therapy, lipid-containing emulsion drops, the secretagogues and, finally, cited some therapeutic agents that are currently being investigated, such as plasma rich in ocular platelets and ophthalmic gels consisting of protein-free veal blood extract and recombinant bovine growth factor.

In summary, Dr. Alonso Aliste showed that dry eye is a common disease after refractive surgery, that its symptoms are worse in the immediate postoperative period and tend to resolve after a few months, which a small percentage of patients continue with persistent dry eye and that it is essential to use an adequate treatment after the intervention. "Let's study the tear before the surgery so as not to cry later," he concluded.

*"Let's study the tear before the surgery so as not to cry"*

## REFERENCES

1. Yin Y, Liu N, Gong L et al. Changes in the Meibomian Gland After Exposure to Intense Pulsed Light in Meibomian Gland Dysfunction (MGD) Patients. *Curr EyeRes.* 2018 Mar;43(3):308-313.
2. Parfitt GJ, Lewis PN, Young RD et al. Renewal of the Holocrine Meibomian Glands by Label-Retaining, Unipotent Epithelial Progenitors. *Stem Cell Reports.* 2016 Sep 13;7(3):399-410.
3. Hwang HS, Parfitt GJ, Brown DJ et al. Meibocyte differentiation and renewal: Insights into novel mechanisms of meibomian gland dysfunction (MGD). *Exp Eye Res.* 2017 Oct;163:37-45.
4. Kim S1, Yoo YS2, Kim HS et al. Changes of meibomian glands in the early stage of post hematopoietic stem cell transplantation. *Exp Eye Res.* 2017Oct;163:85-90.

## THE SOLUTION FOR THE DRY EYE

### DIAGNOSIS AND FOLLOW UP

**me - check®**

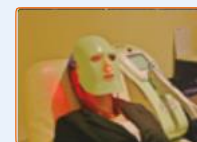

**In only 3 min.**

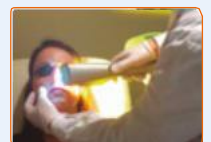**EYELIGHT**




**Modulated light (LLT)**



**Luce pulsata (OPE)**



**Instruments**



**eye - light® line**

**TREATMENT**

