

CLINICAL TECHNIQUES AND TECHNOLOGY

Long-term outcomes after transcanalicular laser dacryocystorhinostomy

Risultati a lungo termine dopo dacriocistorinostomia laser transcanaliculare

F. NUHOGLU, B. GURBUZ, K. ELTUTAR

Department of Ophthalmology, Istanbul Training and Research Hospital, Istanbul, Turkey

SUMMARY

The main objective of the present study was to prospectively evaluate long-term surgical success and safety in patients with nasolacrimal duct obstruction treated with a multidiode transcanalicular laser and bicanalicular silicone intubation stenting. 42 patients treated with transcanalicular laser dacryocystorhinostomy for nasolacrimal duct obstruction were prospectively enrolled. In all cases, silicone stents were inserted. Subjective outcome measure was resolution or improvement of epiphora. Objective outcome measures were patency of the lacrimal system tested with fluorescein and persistence of the nasolacrimal window visualized by nasal endoscopy. The lacrimal system was functional in 95.2% of the patients. The endocanalicular laser DCR failed in two of the 42 (4.8%) cases. External dacryocystorhinostomy was performed successfully on the failed cases. Lacrimal pump syndrome was not seen in any patient. In conclusion, endocanalicular laser dacryocystorhinostomy using a multidiode laser appears to be an effective technique in patients unresponsive to medical therapy.

KEY WORDS: Multidiode laser • Transcanalicular dacryocystorhinostomy • Nasolacrimal duct obstruction

RIASSUNTO

L'obiettivo principale del nostro studio è stato quello di valutare prospetticamente i risultati chirurgici a lungo termine nei pazienti affetti da ostruzione del canale naso lacrimale e sottoposti a chirurgia laser transcanaliculare e posizionamento di stent in silicone. Quarantadue pazienti affetti da ostruzione del canale naso frontale e sottoposti a dacriocistorinostomia laser transcanaliculare sono stati arruolati prospetticamente. In tutti i casi sono stati posizionati al termine della procedura stent in silicone. Il risultato soggettivo è stato valutato sulla base del miglioramento o della completa risoluzione dell'epifora. Il risultato oggettivo, invece, è stato valutato testando la pervietà del dotto naso-lacrimale mediante fluoresceina e verificando la persistenza della breccia nasolacrimale a livello della parete laterale delle cavità nasali in endoscopia nasale. Il 92,5% dei pazienti presentava nel post operatorio vie lacrimali pervie. La dacriocistorinostomia laser endocanalicolare non è stata efficace nel 4,8% de casi in cui si è dovuti ricorrere alla dacriocistorinostomia per via esterna. La "lacrimale pump syndrome" non è stata osservata in nessun paziente. Concludendo, la dacriocistorinostomia endocanalicolare mediante laser a diodi può essere considerata una tecnica efficace nei casi non responsivi alla terapia medica.

PAROLE CHIAVE: Laser a diodi • Dacriocistorinostomia transcanaliculare • Ostruzione del canale naso lacrimale

Acta Otorhinolaryngol Ital 2012;32:258-262

Introduction

In treatment of patients with primary acquired nasolacrimal duct obstruction, external dacryocystorhinostomy (DCR) is the gold standard. DCR was first described by Toti in 1904 as an external approach to the sac through a skin incision in the medial canthus, resecting the adjacent lacrimal sac and nasal mucosa with their intervening bone. In 1921, Dupuy-Dutemps and Bourget, and later Falk et al. in 1961, improved rates of successful fistulization by directly suturing the edges of nasal and lacrimal sac mucosal flaps. For treatment of these patients, alternative techniques to external DCR have been applied such as balloon catheter dilatation, endonasal dacryocystorhinostomy (endonasal DCR) and laser-assisted endonasal

DCR. To increase the success rates of these techniques, silicone intubation and application of mitomycin C have been utilized with increased rates of success¹⁻³.

In 1990, Massaro et al. introduced endonasal laser DCR using a high-energy argon laser device and operating microscope⁴. Near the end of 1980s with the development of high-resolution fiber-optic endoscopes, satisfactory images were obtained, and as a consequence endonasal and transcanalicular laser DCR techniques were launched^{4,5}. Transcanalicular laser dacryocystorhinostomy (TLDCR) was first introduced by Levin et al. using cadavers in 1992⁶. Nowadays, various types of laser techniques have been applied that are becoming to be more widely used, and the long-term results are beginning to be reported.

The present study prospectively evaluated long-term surgical success and safety in patients with nasolacrimal duct obstruction treated with multidiode transcanalicular laser and bicanalicular silicone intubation stenting.

Materials and methods

Study design

The study was approved by the Ethics committee (298/2010). Written informed consent was obtained from all subjects or a legal surrogate. 42 patients treated with TLDCR for nasolacrimal duct obstruction were prospectively enrolled in this non-comparative study. Patients with epiphora, chronic dacryocystitis and dacryostenosis were included. Cases with the presence of intrasaccular adhesions, common canalicular stenosis, acute dacryocystitis, recurrent dacryostenosis, paediatric cases, canalicular stenosis, lacrimal sac neoplasms, dacryolithiasis, fistulous dacryostenoses, predominant bone deformities (posttraumatic or lacrimal sac fossa deformities) and additional intranasal abnormalities were excluded from the study.

Lacrimal system irrigation was applied for all patients presenting with complaints of epiphora. The diagnosis was supported by dacryocystograms obtained after instillation of 480 mg/ml radio-opaque iodine into the sac. Endoscopic examination was performed by otolaryngologists on all patients before surgery.

Surgery was performed under general anaesthesia using a multidiode laser (Intermedical Multidiode S-30 OFT®) device. Surgery was performed by two ophthalmologists. Vasoconstriction was achieved by packing the nasal cavity with cotton sponges soaked in 4% lidocaine and epinephrine (1/100,000), which was left in place 10 min before surgery. Canalicular dilatation was performed, and a transcanalicular diode laser probe of 600 µm fiber optic (silica-fluopolymer) was inserted. Nasal endoscopy to visually

control the tip of the laser probe was performed throughout the procedure. The middle turbinate was infractured medially to enhance access to the lateral wall of the nasal fossa and to protect middle turbinate from laser shots in cases where the middle turbinate was very close to the area of application. The light of the laser probe was transnasally observed, just lateral and superior to the middle turbinate, at the upper third of maxillary line. A 980 nm diode laser was applied through the transcanalicular approach with 500 msec multi-pulse mode at 8-10 W obliterating the overlying nasal mucosa and creating an osteotomy until a size greater than 11 x 4 mm was achieved. Carbonized tissues were removed. The patency of the lacrimal canal was checked with lacrimal irrigation. In addition, the osteotomized region was cleansed with the same irrigation solution. In all cases, bicanalicular silicone stents were inserted. None of the patients received mitomycin C (Figs. 1 and 2).

All patients were postoperatively monitored during the first few days, then weekly for one month, followed by monthly visits for two months, and then every three months up to 42 months by otolaryngologists, and ophthalmologists. Silicone stents were withdrawn at the second postoperative month. During the first week, oral antibiotic prophylaxis (amoxicillin + clavulanic acid 1000 mg b.i.d.), analgesics, anti-inflammatory drugs (naproxen sodium 550 mg b.i.d.) and topical tobramycin ointment 5 times/day were administered. Topical decongestants (xylometazoline hydrochloride 1 mg b.i.d.) were prescribed post operatively for two days. To avoid potential development of allergic conditions against the silicone tube, and to prevent obstruction of the osteotomized area with inflammatory lesions triggered by allergic reactions, topical steroid nasal sprays (fluoromethalone acetate 0.1% 4 times/day) were used until the silicone tube was removed. To avoid possible side effects such as cataract and glaucoma, fluoromethalone steroids were preferred.

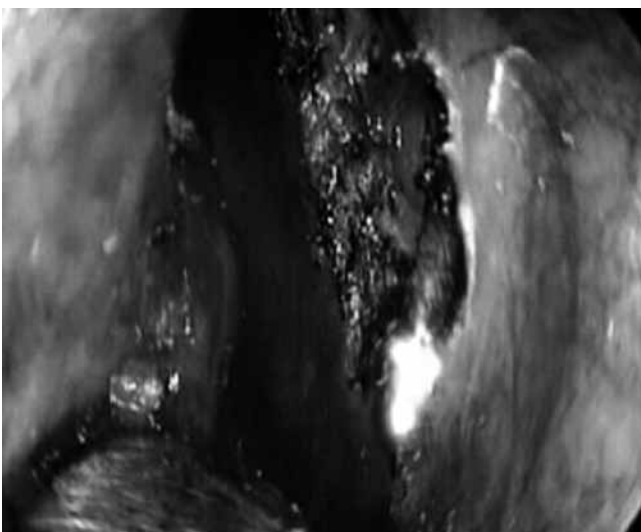


Fig. 1. Creation of an ostium with a laser.

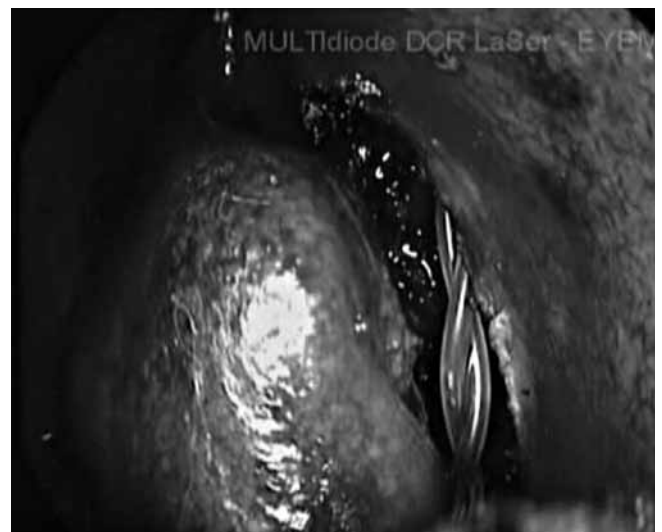

Fig. 2. Bicanalicular silicone intubation stenting.

Outcome measures

At each physical examination, lacrimal irrigations were performed, and patients were queried for the presence of epiphora. Objective outcome measures were obtained by patency testing after lacrimal system irrigation with fluorescein saline. Persistence of the nasolacrimal window was visualized by nasal endoscopy. Osteotomy size was monitored by comparison with the tip of a probe. Cases without epiphora and proven nasal ostium patency demonstrated with free-flow lacrimal irrigation were deemed as successful. Failure was defined as the lack of any improvement in either symptoms or the fluorescein disappearance test.

Statistical analysis

Data were analyzed using the Statistical Package for Social Sciences (SPSS) software (version 15.0 for Windows). All differences associated with a chance probability of 0.05 or less were considered statistically significant. Chi-square and student *t* tests were performed on nominal data.

Results

Patients, 10 (24%) males and 32 (76%) females, ranged in age from 19 to 66 years (mean 52.2 ± 10.7). In all cases, involvement was unilateral. 25 cases (59.5%) had involvement of the right eye, and the other 17 had involvement of the left eye. Mean operative time was determined to be 13.4 ± 5.3 (range 9 to 21) minutes.

Lacrimal system was functional in 95.2% of the patients and the osteotomy size was > 4 mm (Figs. 3 and 4). Age and sex were found to have no statistical significance (*p* ≥ 0.05). The endocanalicular laser DCR failed in two of the 42 (4.8%) cases. There were no complaints of tearing in the other patients. In the first patient undergoing intervention, common canalicular thermal injury developed due to strayed laser emissions, and common canalicular

stenosis developed at the first month. Recurrence at the third month was seen in our second unsuccessful case. In these two patients, successful results were obtained with external DCR and bicanalicular silicone stent intubation. The osteotomized region was monitored using endoscopy. Lacrimal pump syndrome was not seen in any patient.

Discussion

Long-term success rates of laser TCDCR are generally lower than those of external DCR, which is considered to be the “gold standard”⁷⁻⁹. Success rates of external DCR usually range between 85-99%, and are usually greater than 90%^{10 11}. However, the advantages of laser TCDCR over external DCR are lack of scar development, fewer morbidities, no need for general anaesthesia, diminished perioperative and postoperative bleeding, intact pump mechanism because of unaffected medial canthal tendon and a less invasive procedure. The technique can be easily applied under local anaesthesia. In our study, since we are learning and using this technique for the first time, patients were operated under general anaesthesia. Since we have applied this technique only recently, we did not include paediatric cases in the study because of their narrower intranasal operative field. Patients with intrasaccular adhesions, and common canalicular stenosis as demonstrated with dacryocystography, were also excluded. In these cases, thermal damage can develop in the common canalicular region and posterior wall of the lacrimal sac. Success rates of 63-91% (mostly < 85%) have been reported for endonasal DCR technique without the use of laser energy¹²⁻¹⁴. When we compared success rates of DCR and laser TCDCR, similar success rates for both techniques were observed. An endonasal approach has been widely used. For such an approach, various instruments such as cold knife, lasers, punches, radiofrequency units and drills are required^{15 16}. However, endonasal DCR

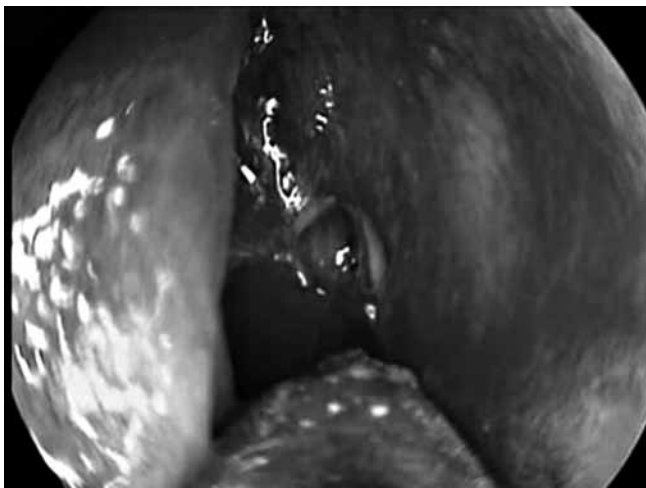

Fig. 3. Size of an ostium at postoperative month 24.

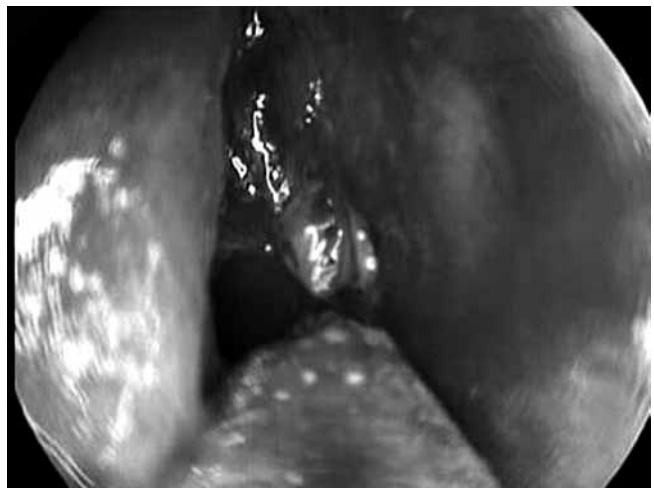


Fig. 4. Passage of fluid through ostium at postoperative month 24.

has some disadvantages such as need for greater number of instruments to be used intranasally, orbital perforation and a long learning curve¹⁷. In laser TCDCR, since the laser probe is not directed to the eye orbit, it is possible to avoid orbital perforation. For endonasal laser DCR, success rates ranging between 58-97% (mostly < 85%) have been reported¹⁸⁻²².

Different success rates have been reported with TCDCR. In the last 10 years, success rates have varied between 59-92%, mostly < 85 percent²³⁻³⁰. The success rate in our study was 95.2%. We attribute this difference to the application of this technique on selected cases by two highly experienced surgeons in the external DCR technique. Besides we think that larger sized ostial openings increase success rates. Since the laser probe we used does not require a guide, an appropriate light angle (0.46°) of our transcanalicular probe make creation of a larger ostium possible. In addition, lower energy is used and less tissue damage occurs with this technique.

Laser TCDCR and external DCR are alternative modalities to endonasal DCR. The absence of skin scars, shorter duration of the operation, shorter learning-curve, lack of orbital perforation risks, need for fewer number of instruments, reproducibility of the techniques, better perioperative and postoperative hemostasis, ease of application by the ophthalmologists, earlier rehabilitation, lower morbidity rates and easy applicability under local anaesthesia have made these techniques attractive alternatives. There are certain disadvantages of this procedure, such as handling and cost of the laser, synechia and granulation tissue formation, common canalicular stenosis and low success rate in paediatric patients. However, because of the aforementioned advantages, we believe that success rates will increase in parallel with advancements in instrumentation and increased surgical experience.

Conclusions

TLDCR using a multidiode laser is well tolerated in patients unresponsive to medical therapy. Further comparative studies are required to clarify the results of multidiode laser use in patients with nasolacrimal duct obstruction.

References

- 1 Wood JR. *Manual of endoscopic lacrimal and orbital surgery*. 1st ed. Philadelphia: Elsevier; 2004.
- 2 Bernardini FP, Moin M, Kresten RC, et al. *Routine histopathologic evaluation of the lacrimal sac during dacryocystorhinostomy*. *Ophthalmology* 2002;109:1214-8.
- 3 Olver J. *Colour Atlas of Lacrimal Surgery*. Oxford: Butterworth-Heinemann; 2002.
- 4 Massaro BM, Gonnering RS, Harris GJ. *Endonasal laser dacryocystorhinostomy: a new approach to nasolacrimal duct obstruction*. *Arch Ophthalmol* 1990;108:1172-6.
- 5 Tsirbas A, Wormald PJ. *Mechanical endonasal dacryocystorhinostomy with mucosal flaps*. *Br J Ophthalmol* 2003;87:43-7.
- 6 Levin PS, Stormogipson DJ. *Endocanalicular laser-assisted dacryocystorhinostomy. An anatomic study*. *Arch Ophthalmol* 1992;110:1488-90.
- 7 Christenbury JD. *Translacrimal laser dacryocystorhinostomy*. *Arch Ophthalmol* 1992;110:170-1.
- 8 Pearlman SJ, Michalos P, Leib ML, et al. *Translacrimal transnasal laser-assisted dacryocystorhinostomy*. *Laryngoscope* 1997;107:1362-5.
- 9 Alanon Fernandez MA, Martínez Fernández A, Cardenas Lara M. *Técnica de dacriocistorrinostomia transcanalicular usando el láser diodo*. *Arch Soc Esp Oftalmol* 2004;79:325-30.
- 10 Hartikainen J, Antila J, Varpula M, et al. *Prospective randomized comparison of endonasal endoscopic dacryocystorhinostomy and external dacryocystorhinostomy*. *Laryngoscope* 1998;108:1861-6.
- 11 Saiju R, Morse LJ, Weinberg D, et al. *Prospective randomised comparison of external dacryocystorhinostomy with and without silicone intubation*. *Br J Ophthalmol* 2009;93:1220-2.
- 12 Erdol H, Akyol N, Imamoglu HI, et al. *Long-term follow-up of external dacryocystorhinostomy and the factors affecting its success*. *Orbit* 2005;24:99-102.
- 13 Woog JJ, Kennedy RH, Custer PL, et al. *Endonasal dacryocystorhinostomy: a report by the American Academy of Ophthalmology*. *Ophthalmology* 2006;113:2378-9.
- 14 Drnovsek-Olup B, Beltram M. *Transcanalicular diode laser-assisted dacryocystorhinostomy*. *Indian J Ophthalmol* 2010;58:213-7.
- 15 Lun Sham C, van Hasselt AC. *Endoscopic terminal dacryocystorhinostomy*. *Laryngoscope* 2000;110:1045-9.
- 16 Tsirbas A, Wormald PJ. *Mechanical endonasal dacryocystorhinostomy with mucosal flaps*. *Br J Ophthalmol* 2003;87:43-7.
- 17 Raoul DH, Ruben GH, Hernando LC, et al. *Use of the diode laser with intraoperative mitomycin C in endocanalicular laser dacryocystorhinostomy*. *Ophthal Plast Reconstr Surg* 2007;23:134-7.
- 18 Szubin L, Ariadna P, Sacks E. *Endonasal laser-assisted dacryocystorhinostomy*. *Am J Rhinol* 1999;13:371-4.
- 19 Ibrahim HA, Batterbury M, Banhegyi G, et al. *Endonasal laser dacryocystorhinostomy and external dacryocystorhinostomy outcome profile in a general ophthalmic service unit: a comparative retrospective study*. *Ophthalmic Surg Lasers* 2001;32:220-7.
- 20 Morgan S, Austin M, Whittet H. *The treatment of acute dacryocystitis using laser assisted endonasal dacryocystorhinostomy*. *Br J Ophthalmol* 2004;88:139-41.
- 21 Maini S, Raghava N, Youngs R, et al. *Endoscopic endonasal laser versus endonasal surgical dacryocystorhinostomy for epiphora due to nasolacrimal duct obstruction: prospective, randomised, controlled trial*. *J Laryngol Otol* 2007;121:1170-6.
- 22 Ben Simon GJ, Joseph J, Lee S, et al. *External versus endoscopic dacryocystorhinostomy for acquired nasolacrimal duct obstruction in a tertiary referral center*. *Ophthalmology* 2005;112:1463-8.

- ²³ Mullner K, Wolf G. *Endoscopic treatment of lacrimal duct stenoses using a KTP laser-report of initial experiences*. *Klin Monatsbl Augenheilkd* 1999;215:28-32.
- ²⁴ Muelner K, Wolf G, Luxenberger W, et al. *Laser-assisted transcanalicular dacryocystorhinostomy. Initial results*. *Ophthalmologie* 2001;98:174-7.
- ²⁵ Maeso Riera J, Sellarés Fabres MT. *Dacriocistorrinostomia transcanalicular con laser diodo; variaciones técnicas y resultados*. *Acta Otorrinolaringol Esp* 2007;58:10-5.
- ²⁶ Alañón Fernandez MA, Alañón Fernandez FJ, Martínez Fernandez A, et al. *Dacriocistorrinostomía endonasal y transcanalicular con láser diodo: resultados preliminares*. *Acta Otorrinolaringol Esp* 2004;55:171-6.
- ²⁷ Alañón Fernandez MA, Alañón Fernandez FJ, Martínez Fernandez A, et al. *Resultados de la aplicación de mitomicina en la dacriocistorrinostomía endonasal y endocanalicular con láser diodo*. *Acta Otorrinolaringol Esp* 2006;57:355-8.
- ²⁸ Henson RD, Henson RG Jr, Cruz HL Jr, et al. *Use of the diode laser with intraoperative mitomycin C in endocanalicular laser dacryocystorhinostomy*. *Ophthal Plast Reconstr Surg* 2007;23:134-7.
- ²⁹ Piaton JM, Keller P, Limon S, et al. *Holmium: YAG and neodymium: YAG laser assisted trans-canalicular dacryocystorhinostomy. Results of 317 first procedures*. *J Fr Ophtalmol* 2001;24:253-64.
- ³⁰ Plaza G, Beteré F, Nogueira A. *Transcanalicular dacryocystorhinostomy with diode laser: long-term results*. *Ophthal Plast Reconstr Surg* 2007;23:179-82.

Received: November 2, 2011 - Accepted: February 29, 2012